

Etymology of Cells in Oral Pathology: A Brief Review

Prajya Bhardwaj^{1,*}, Tabita Joy Chettiankandy¹, Manisha Ahire¹, Garima Dixit¹, Ishu Singhal¹

¹ Government Dental College & Hospital, Mumbai, India.

* Correspondence: prajyabhardwaj101@gmail.com.

Abstract: Etymology is the study of origin and history of words. It links medical science with other disciplines, such as linguistics, history, and anthropology, enriching the understanding of health and disease in a broader context. It provides a foundation for medical vocabulary, making it easier for the students to understand and correlate the terms with different physiological and pathological conditions. An extensive search of literature published in online and offline sources was done and cells in oral pathology were categorized as epithelial or mesenchymal depending upon their origin. A thorough compilation of data was done with emphasis on their etymology, morphology, histochemistry/ immunohistochemistry and physiological/ pathological conditions associated with them along with the hand-made diagram in a tabular format.

Keywords: Cell Morphology; Epithelial Cell; Mesenchymal Cell.

Citation: Bhardwaj P, Chettiankandy TJ, Ahire M, Dixit G, Singhal I. Etymology of Cells in Oral Pathology: A Brief Review. Brazilian Journal of Dentistry and Oral Radiology. 2026 Jan-Dec;5:bjd69.

doi: <https://doi.org/10.52600/2965-8837.bjdor.2026.5.bjd69>

Received: 9 November 2025

Accepted: 8 December 2025

Published: 11 December 2025



Copyright: This work is licensed under a Creative Commons Attribution 4.0 International License (CC BY 4.0).

1. Introduction

Etymology is derived from the ancient Greek word etymon meaning "true sense, original meaning". It is the branch of linguistic science treating with origin and evolution of words. In ancient India, Sanskrit linguists and grammarians were the first to undertake comprehensive analyses of linguistics and etymology. Even though etymological research originated from the philosophical tradition, much current etymological research done in the field of modern medical science.

In medical science; disease, anatomical structure, procedure, or medical discovery can be named after the person who had discovered it; and such terms are known as eponyms, for example, Gargoyl cell, Langerhan cell, Downey cell etc. Although it honours the inventor, it acts as a potential source of confusion as these do not provide clarity regarding its use. Non- eponymous or descriptive terms that provide anatomical or functional clarity are increasingly preferred which are usually Greek or Latin in origin.

A significant number of cells can be encountered in different pathologies, pertaining to oral cavity. These can be categorized as epithelial or mesenchymal depending upon their origin. However, certain cells are grouped under broad umbrella terms, such as 'giant cells', which encompass multiple distinct cellular entities, including osteoclasts, trophoblasts, and Tzanck cells. Because of the wide variety of cell types, it becomes extremely challenging for students to recall and differentiate them. Although eponymous or 'named cells' in oral pathologies have been widely discussed in the literature, a vast knowledge gap still exists regarding the use of non- eponymous or 'unnamed cells'.

This review article aims to compile and summarize the etymology & pathogenic microscopic and immunohistochemical characteristics of the most frequently encountered cells in oral pathology along with line diagram of each cell type. Understanding the word root origin, prefix and suffix will help break down complex terms thereby making the understanding easy and boosting memory.

2. Material and Methods





The inclusion criteria considered cells with well-defined morphology, histochemistry, and immunohistochemistry. Cellular variants with broadly descriptive designations, such as clear cells, giant cells, and granular cells, were excluded. The data sources consulted included standardized textbooks, StatPearls, and indexed journals available in English with free full-text access.







3. Results

The inclusion criteria considered cells with well-defined morphology, histochemistry, and immunohistochemistry. Cellular variants with broadly descriptive designations, such as clear cells, giant cells, and granular cells, were excluded. The data sources consulted included standardized textbooks, StatPearls, and indexed journals available in English with free full-text access.

The cells were classified as either epithelial or mesenchymal based on their origin and then arranged in alphabetical order. Metabolically active cells, such as osteoblasts and fibroblasts, contain prominent organelles, including mitochondria, rough endoplasmic reticulum, and the Golgi apparatus, which were not individually highlighted. The collected data were summarized in a table that included a brief description of each cell's etymology, morphology, staining characteristics, and a corresponding hand-drawn line diagram (Tables 1 and 2).

Table 1: Description of Epithelial cells in oral pathology (original hand drawn diagrams).

Reference	Cell	Etymology & Description	Conditions	Histochemistry/ Immunohistochemistry	Line Diagram
[1]	Acantholytic cell	Acantha: Greek: thorn, lysis: breakdown. Polygonal epithelial cells with loss of intercellular cohesion	- Acantholytic squamous cell carcinoma [ASCC] - Pemphigus vulgaris - Acanthomatous ameloblastoma	- H & E* stain - Decreased expression of dsg ⁺ 1, dsg 3 & E ⁺ cadherin	
[1]	Ameloblast	English: Amel: enamel Blastos: germ Tall columnar polarized cell 40 μ in length and 4-5 μ in width	- Amelogenesis imperfecta - Ameloblastoma - Ameloblastic fibroma - Ameloblastic carcinoma	- H & E Stain - PAS [±] - Alcian Blue - Autoantibodies against amelogenin, ameloblastin	
[2, 3]	Basaloid cell	Latin: basis: foundation Cuboidal to high cuboidal cells having hyperchromatic central nucleus	- Basaloid squamous cell carcinoma - Basaloid salivary gland tumor	- H & E stain	
[4, 5]	Bizarre/monster/	Latin: bizzarro: angry	- Malignant melanoma	- Cyclin D1	

	pleomorphic cell	Atypical cells having multiple nuclei, vesicular chromatin, cherry red nucleoli, abundant pale granular cytoplasm	- Basal cell carcinomas - Dermatofibromas - Pleomorphic fibromas		
[6]	Ghost cell	English: gast: soul Swollen, pale, eosinophilic epithelial cells with pyknotic nuclei and faint cellular outline.	- Calcifying epithelial odontogenic cyst - Dentinogenic ghost cell tumor - Ghost cell odontogenic carcinoma	- Masson's Trichrome stain - Mallory's stain - Van Gieson stain - AE1/AE3**	
[7]	Koilocyte	Greek: koilos: hollow and kytos: cell. Enlarged cell with perinuclear halo and nuclei with irregular border. Nuclei may be multinucleate or raisin shaped	- Herpes simplex virus diseases - Koilocytosis	- H & E Stain	
[8]	Melanocyte	Greek: Melas: black. Dendritic cell, has well developed RER, golgi apparatus, mitochondria, but lack tonofilament & desmosomal connections to adjacent keratinocytes.	- Melanotic macule - Melanotic & Blue nevi - Smoker's melanosis - Oral melanocanthoma - Peutz Jehgers Syndrome - Addison's Disease	- Melan A - HMB- 45 ⁺⁺ - S-100 - SOX-10 ⁺⁺ - Ki-67	
[1]	Mucous cell	Latin: Mucus: slime Cuboidal to pyramidal cells having mucinogen granules	- Mucoepidermoid carcinoma (MEC)	- PAS positive - Mucicarmine	
[9]	Myoepithelial cell/ Basket cell	Greek: mys: muscle, Greek: Epi: upon, Thele: nipple Stellate shaped having branching processes made up of actin & myosin, cell membrane has numerous caveolae which help in contraction.	- Myoepithelioma - MEC - Pleomorphic adenoma - Adenoid cystic carcinoma - Epithelial myoepithelial carcinoma	- Tannic acid-phosphomolybdic acid amidoblack technique - SMA ⁺⁺⁺ - CK 5/6 - p40/ 63 - Caldesmon - Calpontin	
[1, 9]	Oncocyte/Oxyphil cell	Greek: onco: bulk	- Oncocytoma - Warthin's tumor	- PTAH ⁺⁺⁺ - AE1/ AE3	




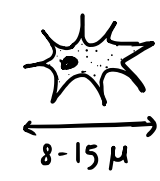

Oncocytes are epithelial cells characterised by abundant mitochondria, granular & eosinophilic cytoplasm, and centrally situated nucleus


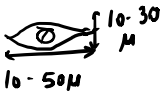




- Oncocytic carcinoma
- Salivary duct carcinoma
- Acinic cell carcinoma




- CK 19^{†††}
- CK 7^{†††}





Legend. *Hematoxylin & Eosin. † Desmoglein. ‡ Periodic Acid Schiff. § Epithelial. ** Anticytokeratin monoclonal antibodies. †† Human melanoma black. ††† Sry-related HMG-BOX gene 10. *** Smooth Muscle Actin. †††† Phosphotungstic acid-hematoxylin. ††††† Cytokeratin.

Table 2: Description of connective tissue cells in oral pathology (original hand drawn diagrams).

Reference	Cell	Etymology & Description	Conditions	Histochemistry/ Immunohistochemistry	Line Diagram
[1]	Adipocyte/ Lipocyte	Latin: Adipo: fat, Round cell [70-120 μ diameter] with cytoplasmic rimming/ signet ring appearance	- Lipoma - Liposarcoma	- Sudan III, IV - Oil red O, Sudan Black O - ASC-1*	
[10]	B lymphocyte	B - bone marrow in humans Latin: Lympha: clear fluid Greek: kytos: cell, 9-15 μ round cell with deeply basophilic large nucleus and scanty cytoplasm	- B cell lymphoma - Multiple myeloma - B cell lymphoproliferative disease	- H & E stain - CD 9, 24 † - CD 10 – early stage of B cell lineage; CD19 & 20 [all cells of B cell lineage except plasma cells] - CD 27 [plasma & memory cell]	
[11]	Basophil	Greek: basis: bottom, Greek: Philos: loving, 10-12 μ, Large granules [0.5 μ] containing heparin & chondroitin sulphate	- Anaphylaxis	- CD 200	
[12]	Cementocyte	Latin: caementum: broken stone. Squamoid, oval/ round [8-15 μ] having large eccentric nuclei & basophilic cytoplasm. Possess canaliculi, upto 1 μ diameter & 15 μ length.	- Cementoma	- Fibromodulin - Lumican	
[11]	Centrocyte	Latin: center: mid- point of a circle. Cell having 8-12 μ diameter, scant cytoplasm, angulated indented nuclei, coarse chromatin & indistinct nucleoli	- Diffuse large B cell lymphoma	- While differentiating from centroblast to centrocyte, it loses CD27 and acquired CD 40 [finally converting into B memory cell]	

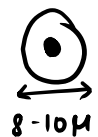[13]	Chondrocyte	<p>Greek: khondros: cartilage.</p> <p>Flat to round with euchromatic nuclei, prominent mitochondria, endoplasmic reticulum, golgi complex and substantial glycogen.</p>	- Osteoarthritis	- Transcription factors Sox 5, 6 & 9 - Structural proteins collagen type II and α -1 aggrecan	 <p>lacunae</p>
[11]	Endothelial cell	<p>Greek: endon: within; Thele: nipple. Thin elongated cells 10- 50 μ long, 10- 30 μ wide, and 0.1- 10 μ thick, contains Weibel- Palade bodies [0.1 μ wide & 3 μ long]</p>	<p>- Pyogenic granuloma</p> <p>- Pregnancy tumor</p>	<p>- Von- Willebrand factor</p> <p>- Angiotensin converting enzyme</p> <p>- P- selectin</p>	 <p>10-30 μ 10-50 μ</p>
[14]	Eosinophil	<p>Greek: eosin: rose dye, phil: loving, cell having 12-17 μ diameter, bilobed nuclei no nucleoli. 4 types of granules-Crystalloid, Primary, Small & Secretory granules [0.5-1.5 μ long & 0.3 -1 μ wide]</p>	<p>- Cushing syndrome</p> <p>- Sepsis</p>	<p>- CD9</p> <p>- CD11 b</p> <p>- CD 11 c</p> <p>- CD 23</p> <p>- CD162</p>	 <p>12-17 μ</p>
[15]	Epithelioid cell	<p>Activated macrophages resembling epithelial cells. Indistinct shape, finely granular having pale eosinophilic cytoplasm, central ovoid nuclei and prominent golgi apparatus.</p>	<p>- Epithelioid cell histiocytoma</p> <p>- Hodgkin's Lymphoma [Mixed cellularity type]</p>	<p>- Malignant mesothelioma</p> <p>- Epithelioid sarcoma</p>	
[11]	Erythrocyte/ Red blood cell	<p>Greek: erythros: red, kytos: cell</p> <p>7.2- 7.4 μ biconcave disk: Outer disk: 2.2 μ & Inner disk: 1μ in diameter</p>	<p>- Anemia</p> <p>- Thalessemia</p>	<p>- ABO and Rh antigen</p>	 <p>7.2-7.4 μ</p>
[16, 17]	Fibroblast	<p>Latin: <i>fibra</i>: fibre, Greek: kytos: cell. Spindle shaped cell</p>	<p>- Fibrosarcoma</p>	<p>- Masson's Trichrome stain</p> <p>- Mallory's Aniline Blue stain</p>	 <p>15-25 μ</p>

		[15-25 μ] having large flat pale staining euchromatic nucleus, prominent nucleoli and cytoplasmic extensions.	- Solitary fibrous tumor - Fibrous dysplasia - Nodular fasciitis - Nasopharyngeal angiofibroma	- Van Gieson stain	
	Gargoyle cell/ Hurler cell	French: gargouille: gargling sound. Large oval or polygonal cell 20 μ in diameter	- Hurler's syndrome	- Alcian Blue - Toluidine blue	
[18]		having pale cytoplasm; either agranular or finely granular with crescent shaped nuclei.			
	Histiocyte/ Clasmatocyte	Greek: histion: tissue, kytos: cell large cell with distinct oval, indented nucleus and abundant cytoplasm. Cytoplasmic granules may or may not be present.	- Langerhans cell histiocytosis - Multiple sclerosis	- CD 68 - CD 163	
[11]					
	Lacunar cell	Latin: lacuna: cavity. Variant of Reed Sternberg Cell having 30-50 μ diameter, multilobed nuclei & pale cytoplasm. Lacuna is created as a result of fixation artefact.	- Hodgkins lymphoma	- H & E stain	
[15]					

[18]	<p>Macrophage</p> <p>Greek: macros: large, phage: eater. Phagocytic cell [12 μ diameter] with eccentric nuclei having indented oval or kidney bean shape with numerous lysosomes.</p>	<p>- Oral lichen planus</p> <p>- Oral squamous cell carcinoma</p> <p>- Multiple sclerosis</p>	<p>- Tumor associated macrophages: PDL2**, CCR2⁺⁺, CD40 antibodies</p> <p>- Pan M1 & M2- MHC⁺ II, CCR5⁺⁺</p>	
[19]	<p>Mast cell/ Mastocyte/ Histamino- cyte/ Labro- cyte</p> <p>German: Mastzellen: well fed. Oval, pyriform, spindle, star shaped cell due to aggregation of intracytoplasmic granules [0.2-0.4 μ]; nucleus [4 μ diameter] having round-oval, fusiform or kidney shaped.</p>	<p>- Oral lichen planus</p> <p>- Oral submucous fibrosis</p> <p>- Oral leukoplakia</p> <p>- Oral squamous cell carcinoma</p>	<p>- Crystal violet</p> <p>- Methylene blue</p> <p>- Methylene violet</p> <p>- Acridine red</p> <p>- CD 45</p> <p>- CD 117</p>	
[11]	<p>Monocyte</p> <p>Greek: Mono: single, Kytos: cell 15-22 μ in diameter, ellipsoidal nucleus, often indented giving kidney shape/ lobulated appearance & azurophilic granules.</p>	<p>- Monocytosis:</p> <p>[i] Chronic inflammation</p> <p>[ii] CML⁺⁺⁺</p> <p>- Monocytopenia in Immune therapy</p>	<p>- CD 14</p> <p>- CD 16</p>	
[20]	<p>Neutrophil /PMNL***/ polys/ mi- crophage</p> <p>Greek: neutron: neutral, phil: loving. Round to oval cell with 10-12 μ diameter; multilobed nuclei usually 3-5 lobes. 4 types of granules- 1°/ azurophilic; 2°/ specific;</p>	<p>- Acyclic Neutropenia</p> <p>- Agranulocytosis</p> <p>- Papillon- Lefevre Syndrome</p>	<p>- Arginase 1</p> <p>- CD 14</p> <p>- CD 15</p> <p>- CD 63</p>	

	Tertiary/ gelatinase & Secretory vesicles	- Leukocyte adhesion deficiency Syndrome		
[1]	Odontoblast Odonto: tooth, Greek: Blast: germ. Columnar cell 25-40 μ in length & 5-7 μ in width. In root region → ovoid/ spindle shaped	- Physiological	- H & E stain - Masson's stain - Masson- Goldner stain	
[21]	Osteoclast Greek: osteon: bone, klas- tos: broken. Dome shaped multinucleated cell [upto 300 μ in size & 100 nuclei] having ruffled border adjacent to the bone undergoing resorption.	- Osteopetrosis - Osteoporosis - Osteoarthritis - Adult T cell leukemia	- CD13, CD14, and CD68. - Lack of CD56, GrB, and Ki67 expression help distinguish osteoclasts from macrophages and giant cells.	
[11]	Osteocyte Greek: osteon: bone, Kytos: cell Entrapped osteoblast, having comparatively less cellular organelles than osteoblast, possess cell processes known as canaliculi.	- Osteoporosis - Hypophosphatemic rickets - Bone tumor metastasis	- PHEX**** - Podoplanin for early osteocytes; RANKL***, Sclerostin, FGF23**, and matrix extracellular phosphoglycoprotein [MEPE] for mature osteocytes	
[22, 23]	Pericyte/ Mural cell Pale staining fibroblast-like cells with extensive cytoplasmic projections that	- Pericytoma	- Desmin - CD 146 - PDGFBR*****	

		wrap around arterioles, ca-		
		pillaries & venules		
	Plasma cell	Greek: plasma: something	- Plasma cell mye-	- CD 79a
		created, kytos: cell. Round	loma	- CD 38
		to ovoid cell having 14-20 μ	- Plasmacytoma	- CD 138/ Syndecan 1
		diameter, basophilic cyto-	- Amyloidosis	
[22]		plasm, perinuclear halo ec-	- Plasma cell defi-	
		centrically placed cartwheel	ciency disorders	
		shaped nuclei; may contain		
		cytoplasmic inclusions-Rus-		
		sell bodies [2-3 μ]		
	T lympho-	T- thymus, Latin: <i>Lympha</i> :	T cell lymphoma	- CD 3
	cyte	clear fluid, Greek: kytos: cell		- CD 4
		8-10 μ in diameter, large		- CD 8
[24]		nucleus, dense hetero-chro-		
		matin, a few mitochondria,		
		ribosomes, & lyzosomes.		



Legend. *Adipocyte specific cell. †Cluster of differentiation. **Programmed cell death ligand. ††C-C motif chemokine receptor 2 & 5. ‡ Major histocompatibility complex. ***Polymorphonuclear leukocyte. ††† Chronic myelomonocytic leukemia. ****Phosphate Regulating Endopeptidase X-Linked. †††† Receptor activator of nuclear factor-κB ligand. ‡‡ Fibroblast growth factor 23 although osteoclasts fall under the broader category of giant cells, the term 'giant' is considered too generic and therefore has not been cited independently. ***** Platelet-derived growth factor receptor beta.

4. Discussion

'Pathology' is derived from a Greek word 'pathos' meaning disease. It is a rapidly expanding and ever-changing field and lays the foundation for understanding diseases. Cellular pathology, also known as anatomical pathology, is a branch of pathology that deals with the examination of tissues at the cellular level using a microscope. The human body is composed of thousands of distinct cell types, making its study both fascinating and, at times, overwhelming without a structured approach. In Oral pathology, several cellular entities are recognized by eponyms which have been discussed in literature by various authors. However, there appears to be a lack of comprehensive documentation on the 'unnamed' or non-eponymous cells, making it academically challenging for students to remember.

To address this knowledge gap, an extensive literature review was conducted, and the relevant data were systematically compiled, along with hand drawn illustrations of the most observed cells in Oral Pathology. However, due to limitation of words, various other entities could not be added. Some entities like 'epitheloid cell'

came like an eye opener because despite the word 'epithelium' in it, it is of connective tissue origin.

In addition, certain cells decipher multiple entities like 'giant cells' which includes Osteoclast, Reed sternberg cell; or dendritic cells including Langerhans cells, melanocytes etc. that have been excluded from the table. A few surface markers are overlapping and not pathognomonic of a particular disease, for example, CD 200 is expressed in all leukocytes, but maximum expression is seen in basophils; similarly, CD 34 reflects the hematopoietic origin and not an individual cell type. Thorough knowledge about the cells not only contributes in the academic benefits, but also aids in accurate disease diagnosis, consequently improving the treatment outcomes.

5. Conclusion

Oral pathology subject represents a vast domain of different cell types. As much as it is fascinating, it is equally difficult for students to remember, if not dealt with strategically. Understanding complex cellular terms by breaking them down in the form of prefix or suffix will help students in comprehending, rather than just memorizing. Beyond the academic enrichment, this article can be as a reference guide for students as well as pathologists for accurate disease diagnosis, ultimately benefiting patient care.

Funding: None.

Research Ethics Committee Approval: None.

Acknowledgments: None.

Conflicts of Interest: None.

Supplementary Materials: None.

References

1. Berkovitz BK, Holland GR, Moxham BJ, Oral anatomy, histology and embryology E-book; 5th edition; Elsevier Health Sciences; 2017.
2. Jayasooriya PR, Tilakaratne WM, Mendis BR, Lombardi T. A literature review on oral basaloid squamous cell carcinomas, with special emphasis on etiology. *Ann. Diagn. Pathol.* 2013; 17:547-51. doi: 10.1016/j.anndiagpath.2013.09.001
3. Seethala RR. Basaloid/blue salivary gland tumors. *Modern Pathology.* 2017; 30: S84-95. doi: 10.1038/modpathol.2016.190
4. Kumar GS. *Orban's Oral Histology & Embryology.* 15th edition, Philadelphia: Elsevier Health Sciences; 2023.
5. Boyd AS, Wu H, Shyr Y. Monster cells in malignant melanoma. *Am J Dermatopathol.* 2005 Jun 1; 27:208-10. doi 10.1097/01.dad.0000158294.23630.ef.
6. Chavhan SU, Dhanawade SS, Fukate C, Bansal SP. Ghost cell. *J Oral Maxillofac Pathol,* 2021;25: 195-7. doi 10.4103/jomfp.jomfp_112_21
7. Shafer WG, Hine MK, Levy BM. *Shafer's textbook of oral pathology.* 10th edition. Philadelphia: Elsevier; 2024
8. Barrett AW, Scully C. Human oral mucosal melanocytes: a review. *J. Oral Pathol* 1994; 23:97-103. doi: 10.1111/j.1600-0714.1994.tb01095.x.
9. Balachander N, Masthan KM, Babu NA, Anbazhagan V. Myoepithelial cells in pathology. *J Pharm Bioallied Sci.* 2015 Apr;7(Suppl 1): S190-3. doi: 10.4103/0975-7406.155898
10. Althwaiqeb SA, Fakoya AO, Bordoni B. Histology, B-Cell Lymphocyte. 2024 Oct 13. In: StatPearls [Internet]. Treasure Island (FL): StatPearls Publishing; 2025 Jan.
11. Brown JR. *Ham's Histology.* 9th edition, Philadelphia, Lippincott, 1987.
12. Provenza DV. *Fundamentals of oral histology and embryology.* Philadelphia: Lippincott, 1988.

13. Campbell DD, Pei M. Surface markers for chondrogenic determination: a highlight of synovium-derived stem cells. *Cells*. 2012; 1:1107-20. doi. 10.3390/cells1041107
14. Hogan SP, Rosenberg HF, Moqbel R, Phipps S, Foster PS, Lacy P, Kay AB, Rothenberg ME. Eosinophils: biological properties and role in health and disease. *Clin. Exp. Allergy*. 2008; 38:709-50. doi: 10.1111/j.1365-2222.2008.02958.x.
15. Patsouris E, Noel H, Lennert K. Cytohistologic and immunohistochemical findings in Hodgkin's disease, mixed cellularity type, with a high content of epithelioid cells. *Am J Surg Pathol*. 1989; 13:1014-22. doi: 10.1097/00000478-198912000-00003.
16. Vijayashree RJ, Sivapathasundharam B. The diverse role of oral fibroblasts in normal and disease. *J. Oral Maxillofac. Pathol*. 2022; 26:6-13. doi: 10.4103/jomfp.jomfp_48_22.
17. Baranov E, Hornick JL. Soft Tissue Special Issue: Fibroblastic and Myofibroblastic Neoplasms of the Head and Neck. *Head Neck Pathol*. 2020 Mar;14(1):43-58. doi: 10.1007/s12105-019-01104-3.
18. Desai KM, Kheur S, Ghoshal S, Govin-dool SR. Diverse roles of macrophages in oral inflammatory and benign lesions - A narrative review. *Oral Maxillofac Pathol J* 2022; 13:146-149.
19. Weller CL, Collington SJ, Williams T, Lamb JR. Mast cells in health and disease. *Clin. Sci*. 2011; 120:473-84. doi: 10.1042/CS20100459
20. Rashmi SM, Alka DK, Ramakant SN. Neutrophils in health and disease: An overview. *J. oral maxillofac. Pathol*. 2006 Jan 1;10:3-8. doi 10.4103/0973-029X.37740
21. Khan IA, Bordoni B. Histology, osteoclasts. In: StatPearls [Internet]. Treasure Island (FL): StatPearls Publishing; 2025-. Updated 2023 Apr 24.
22. Khamis Y, Arafat W. Tumor microenvironment manipulation and cancer metastasis: taming the beast. In: *Unraveling the complexities of metastasis*. Cambridge (MA): Academic Press; 2022. p. 209-34. doi 10.1016/B978-0-12-821789-4.00003-5
23. Birbrair A. Pericyte biology: development, homeostasis, and disease. *Adv Exp Med Biol*. 2018;1109 .doi: 10.1007/978-3-030-02601-1_1
24. Fabbri M, Smart C, Pardi R. T lymphocytes. *Int J Biochem Cell Biol*. 2003;35. doi: 10.1016/s1357-2725(03)00037-2.
25. James A, Cheigo DJ. *Essentials of oral histology and embryology: a clinical approach*. 5th edition, Philadelphia: Elsevier Health Sciences; 2019.
26. Widbiller M, Rothmaier C, Saliter D, Wölflick M, Rosendahl A, Buchalla W, Schmalz G, Spruss T, Galler KM. Histology of human teeth: standard and specific staining methods revisited. *Arch Oral Biol*. 2021;127. doi: 10.1016/j.archoralbio.2021.105136
27. Shrestha A, Marla V, Shrestha S, Neupane M. Giant cells and giant cell lesions of oral cavity: a review. *Cumhur Dent J*. 2014;17. doi10.7126/cdj.58140.1008002428
28. Bancroft JD, Gamble M. *Theory and practice of histological techniques*. 6th ed. Philadelphia: Churchill Livingstone, Elsevier Health Sciences; 2008.