

# Fourth molars as supernumeraries: a case report

Diego Thiers Oliveira Carneiro <sup>1,\*</sup>

<sup>1</sup> Post-graduate Program in Pathology, Federal University of Ceara, Fortaleza, CE, Brazil.

\* Correspondence: diego\_thiers@hotmail.com.

**Abstract:** Not applied.

**Keywords:** Supernumeraries; Molars teeth; Case Report.

**Citation:** Carneiro DTO. Early Diagnosis and Conservative Treatment of a Large Odontoma in an 8-Year-Old Male Patient. Brazilian Journal of Dentistry and Oral Radiology. 2022 Jan-Dec;1:bjd3.

doi: <https://doi.org/10.52600/2965-8837.bjdor.2022.1.bjd3>

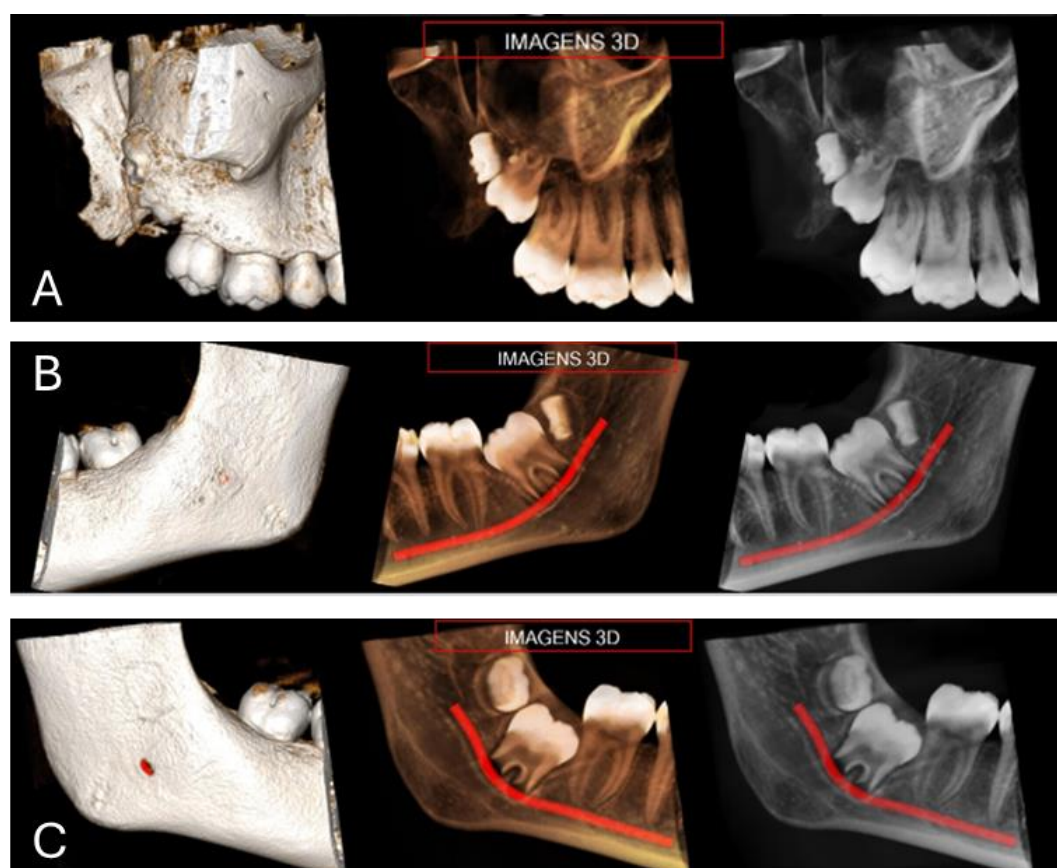
Received: 7 January 2022

Accepted: 22 February 2022

Published: 18 March 2022



**Copyright:** This work is licensed under a Creative Commons Attribution 4.0 International License (CC BY 4.0).



**Figure 1:** Tomographic image showing the upper right third molar (A), lower left third molar (B) and lower right third molar (C) associated with supernumerary tooth.

In these clinical tomographic images, a condition of supernumerary teeth is re-vealed in a 16-year-old female patient who underwent routine examination as a re-quirement for orthodontic planning. The focus of this radiographic analysis centers on the occurrence of three supernumerary molars, a condition that has a prevalence of 2% in the population. The tomography illustrates images, highlighting the presence of supernumerary molars adjacent to teeth 18, 38, and 48 (Figures 1A, 1B and 1C). Supernumerary molars are

surplus teeth that exceed the typical dental formula, and their occurrence is relatively uncommon, especially in the molar region. In this case, radiographic evidence reveals the simultaneous presence of three supernumerary molars, indicating a deviation from the norm [1].

An analysis of tomographic slices reveals the precise anatomical locations of these supernumerary molars. Their positions relative to the existing dentition and neighboring structures are crucial for surgical planning. The supernumerary molars are clearly evident and are impacted. It is important to note that, in many cases, the presence of supernumerary teeth is not associated with specific known causes and may occur in isolation [2]. The diagnosis and treatment of supernumerary teeth typically involve clinical and radiographic assessment for appropriate management, especially when associated with broader genetic conditions.

The clinical context adds complexity to the scenario, as the patient sought tomographic examination in conjunction with orthodontic planning. Consequently, a multidisciplinary approach is necessary to address both orthodontic and surgical aspects of the case. The recommended treatment plan involves the removal not only of supernumerary molars but also of third molars, which are also visualized in the tomographic image. The decision to extract supernumerary molars and third molars is justified based on several considerations. Firstly, the presence of supernumerary molars can disrupt the normal alignment of the dental arch, potentially leading to malocclusions and orthodontic challenges. Secondly, the extraction of third molars is a preventive measure, as their eruption may be associated with complications such as impaction, crowding, or other issues that could compromise overall oral health [3].

The tomographic image serves not only as a diagnostic tool but also as a basis for treatment planning. The accuracy of this imaging modality allows for a detailed assessment of the number, position, and morphology of supernumerary molars and third molars. This information is invaluable for formulating a personalized surgical and orthodontic strategy, emphasizing the importance of an integrated approach to ensure optimal outcomes for the patient. In conclusion, the clinical tomographic image portrays a distinct scenario of three supernumerary molars in a 16-year-old female patient undergoing orthodontic planning. The complexity of the case requires a thorough understanding of anatomical nuances and collaborative efforts between surgery and orthodontics. The proposed treatment plan involves the judicious removal of supernumerary molars and associated third molars, demonstrating a comprehensive approach to address both aesthetic and functional aspects of the patient's oral health.

**Funding:** None.

**Research Ethics Committee Approval:** We affirm that the participant consented to the research by endorsing a clear consent document, and the investigation adhered to the ethical standards outlined in the Helsinki Declaration.

**Acknowledgments:** None.

**Conflicts of Interest:** None.

**Supplementary Materials:** None.

## References

1. Cai X, Cui L, Chen K. Impacted Right Maxillary Third Molar Fused with Supernumerary Tooth. *J Coll Physicians Surg Pak*. 2020 May;30(5):552. PMID: 32580862.
2. Sarica I, Derindag G, Kurtuldu E, Naralan ME, Caglayan F. A retrospective study: Do all impacted teeth cause pathology? *Niger J Clin Pract*. 2019 Apr;22(4):527-533. PMID: 30975958.
3. Anthonappa RP, King NM, Rabie AB. Aetiology of supernumerary teeth: a literature review. *Eur Arch Paediatr Dent*. 2013 Oct;14(5):279-88. PMID: 24068489.